

Original paper

Hepatic effect of sofosbuvir and daclatasvir in thioacetamide-induced liver injury in rats

Mohamed A. Ibrahim, Asmaa Abdel-Aziz, Azza El-Sheikh, Maha Kamel, Al-Zahraa Khalil, Hisham Abdelhaleem

Faculty of Medicine, Minia University, Egypt

Abstract

Introduction: The study aimed at investigating the hepatic effect of direct acting anti-hepatitis C virus drugs (DAAs), sofosbuvir (Sof) and daclatasvir (Dac), in thioacetamide (TAA)-induced liver injury in rats.

Material and methods: Animals were allocated to 7 groups: a normal control group, a TAA group (receiving TAA 50 mg/kg, i.p. twice weekly), two TAA groups receiving either a low or a high dose of Sof (Sof-L and Sof-H; 41.1 mg/kg and 82.2 mg/kg, respectively), two TAA groups receiving either a low or a high dose of Dac (Dac-L and Dac-H; 6.2 mg/kg and 12.4 mg/kg, respectively), and a TAA group receiving both Sof-L and Dac-L.

Results: After 6 weeks, TAA significantly elevated the serum activities of liver enzymes, along with histopathological evidence of liver injury. These findings were associated with a significant increase in a fibrotic marker (tissue inhibitor metalloproteinase-1 – TIMP-1), proinflammatory cytokine (tumor necrosis factor alpha – TNF- α), and oxidative stress parameters (malondialdehyde [MDA] content, and superoxide dismutase [SOD] and catalase activities) in hepatic tissue. TAA rats treated with Sof-L, Dac-L, Dac-H and a combination of Sof-L plus Dac-L showed significant amelioration of TAA-induced liver injury. Their effects were accompanied by a significant reduction in TIMP-1, TNF- α and oxidative stress parameters in hepatic tissue. Interestingly, Sof-H caused no improvement in TAA-induced hepatic injury.

Conclusions: The hepatic effects of Sof and Dac in TAA-induced liver injury appeared to be mediated by anti-oxidant effects, and inhibition of TNF- α and TIMP-1.

Key words: daclatasvir, sofosbuvir, liver injury, thioacetamide.

Address for correspondence

Prof. Mohamed A. Ibrahim, Faculty of Medicine, Minia University, 61511 El-Minia, Egypt, e-mail: mabdellah69@mu.edu.eg

Introduction

Chronic liver infection with hepatitis C virus (HCV) is a universal medical problem that affects about 180 million people worldwide. It may lead to liver cirrhosis and hepatocellular carcinoma [1]. Recently, the standard treatment for chronic HCV has been shifted from interferon-based therapy to direct acting antivirals (DAAs). These drugs represented a revolution in treatment outcomes, yielding a virological response that exceeds 90% compared with less than 50% in interferon-based therapy [2].

The DAAs act by direct inhibition of HCV replication via inhibition of nonstructural (NS) viral pro-

teins [3]. The most commonly used regimen of DAAs is sofosbuvir (Sof)-based therapy. A combination of Sof (400 mg/kg/day) and daclatasvir (Dac) (60 mg/kg/day) showed high efficacy in treatment of almost all HCV genotypes [4, 5].

The direct effect of DAAs in liver injury has not been studied before. Recent studies pointed to promising effects of DAAs in liver fibrosis. Bernuth *et al.* (2015) reported that Sof improved biomarkers of liver fibrosis in HCV-infected patients [6]. A study by Abdel-Aziz *et al.* (2017) concluded that treatment of HCV-genotype 4 patients with a combination of Sof and Dac showed an initial ameliorative effect on liver fibrosis [7]. On the other hand, it has been reported

that administration of Sof in patients with advanced liver diseases caused a hepatotoxic effect that might be attributed to the accumulation of a high concentration of its metabolites [8]. Moreover, Sof belongs to the nucleoside analogues that have been subjected to intense investigation, with a controversy regarding their hepatic effects, whereas both hepatoprotective and hepatotoxic effects have been reported [9-11].

Such observations raised a question whether the hepatic effects of DAAs are attributed only to the resolution of the virus and its inflammatory consequences or are due to some direct effects of the drugs [12, 13]. Consequently, the present study aimed at investigating the effects of Sof and Dac on liver injury induced by thioacetamide (TAA) in rats and possible mechanisms underlying their effects.

Material and methods

Drugs and chemicals

Thioacetamide powder was purchased from Sigma-Aldrich Co. (St. Louis, MO, USA). Sof and Dac powders were obtained from Marcyrl Pharmaceutical Co. (El Obour City, Cairo, Egypt). They were dissolved in distilled water and freshly prepared before use. Commercial kits to measure the activities of alanine aminotransferase (ALT), aspartate aminotransferase (AST), alkaline phosphatase (ALP) and catalase were purchased from Biodiagnostic Co. (Dokki, Giza, Egypt). Kits for assessment of tumor necrosis factor- α (TNF- α) and tissue inhibitor metalloproteinase-1 (TIMP-1) were purchased from Sigma-Aldrich Co. (St. Louis, MO, USA) and Kamiya Biomedical Co. (Seattle, WA, USA), respectively.

Animals

Fifty-six male Wister rats (250-300 g) were obtained from the National Research Center (Dokki, Giza, Egypt). Rats were fed a standard diet of commercial rat chow and tap water and left to acclimatize to the laboratory environment for 2 weeks prior to inclusion in the experiment. The facilities were maintained at $24 \pm 2^\circ\text{C}$ with a 12-h dark: light cycle. Procedures involving rats complied with the ARRIVE guidelines and were performed in accordance with the U.K. Animals Act, 1986. Animals are treated as humans to minimize any suffering.

Experimental design

Animals were allocated to 7 groups (8 rats per group). Group 1 served as the control group, receiving

vehicle. The other six groups were injected with TAA (50 mg/kg i.p.) twice weekly starting on the first day and continuing for 6 weeks [14, 15]. Of the other 6 groups, one served as a non-treated TAA group, two were treated with Sof in either low or high dose (Sof-L and Sof-H; 41.1 mg/kg and 82.2 mg/kg, respectively), two groups were treated with Dac in either low or high doses (Dac-L and Dac-H; 6.2 mg/kg and 12.4 mg/kg, respectively) and one was treated with a combination of Sof plus Dac in low doses as indicated.

Sof and Dac were freshly prepared in distilled water. Each drug was given as a single oral dose (by gavage) for 6 weeks. The low doses of Sof and Dac used in the current study were calculated to be equivalent to the therapeutic human doses according to the following formula:

$$\text{Human equivalent dose (mg/kg)} = \text{animal dose (mg/kg)} \times \frac{\text{animal } K_m}{\text{Human } K_m}$$

where K_m is a correction factor reflecting the relationship between body weight and body surface area. For a typical 60 kg adult human, the K_m is 37, whereas for rat the average K_m is 6 [16]. High doses of Sof and Dac used in the current study were calculated by doubling the low dose.

Sample collection and storage

At the end of the experimental period, the animals were anesthetized with urethane (1.5 g/kg i.p.) and weighed. Blood samples were collected from the abdominal aorta, centrifuged at 5000 rpm for 10 minutes for collection of sera, which were aliquoted in several microcentrifuge tubes to avoid thaw/refreeze and stored at -20°C until use. The liver was gently dissected, cleaned with saline and weighed. A slice of each liver was fixed in 10% formalin and the rest was homogenized in phosphate buffered solution. The homogenate was centrifuged for 15 min at 5000 rpm and the supernatant was aliquoted into several microcentrifuge tubes and kept at -20°C until use.

Assessment of serum liver enzymes and tissue oxidative stress parameters

Sera were used for assessment of the activity of liver enzymes: ALT, AST and ALP. Determination of ALT and AST was done using enzymatic kinetic kits according to the kits' instructions. Hepatic tissue homogenate supernatant was used for determination of oxidative stress parameters. Liver content of lipid peroxides was determined biochemically by spectrophotometric assessment using thiobarbituric acid, as

previously described, based on the reaction of thiobarbituric acid with malondialdehyde (MDA) [17], and results were expressed as nmol/g tissue. Enzymatic activity of superoxide dismutase (SOD) was determined by the method described by Marklund and Marklund based on the fact that the autoxidation of pyrogallol was inhibited by SOD [18]. Catalase activity was determined using an enzymatic colorimetric kit according to the kit instruction, based on the reaction of catalase with a known quantity of H₂O₂ [19].

Determination of TNF- α and TIMP-1 in hepatic tissue

TNF- α in liver homogenate was assayed by an enzyme-linked immunosorbent assay. TIMP-1 in liver homogenate was assessed using a sandwich enzyme immunoassay kit according to the kit's instructions.

Histopathological examination of hepatic tissue

After fixation in 10% formalin solution, liver slices were dehydrated in ascending grades of alcohol and embedded in paraffin. Four-micron-thickness sections were mounted on glass slides and stained with either H&E or Masson trichrome stain. The latter stain is frequently used to differentiate between collagen and smooth muscle in tumors and to identify increases in collagen tissue in liver diseases. Each slide was examined under the light microscope and blindly scored for the presence of hepatic lesions according to Ishak grading for hepatic fibrosis [20].

Statistical analysis

Results were expressed as means (standard error of mean [S.E.M.]). One-way analysis of variance (ANOVA) followed by Tukey's test was used to analyze the results for statistically significant difference. *P* values less than 0.05 were considered significant. Graph Pad Prism software was used for statistical calculations (version 5.01 for Windows, GraphPad Software, San Diego California USA, www.graphpad.com).

Results

Effect of sofosbuvir and daclatasvir on liver enzymes

In TAA rats (model group), there was a significant increase in serum activities of ALT, AST and ALP compared with the normal control group (Table 1). In

TAA groups receiving either Sof and/or Dac in low doses, or Dac in a high dose, rats showed a significant reduction in serum activities of the aforementioned liver enzyme when compared with the model group. In the TAA group treated with high dose of Sof, there was no significant effect on liver enzymes as compared to the TAA model group.

Effect of sofosbuvir and daclatasvir on oxidative stress parameters in hepatic tissue

The model group (TAA group) showed a significant increase in MDA content in hepatic tissue, with a significant decrease in the activities of SOD and catalase enzymes (Table 2). In TAA rats treated with either Sof and/or Dac in low doses, there was a significant decrease in MDA content, with a significant increase in SOD and catalase activities compared with the

Table 1. Effect of sofosbuvir and daclatasvir on liver enzymes

	ALT (U/l)	AST (U/l)	ALP (U/l)
Control	28 ± 4	35 ± 5	262 ± 21
TAA	318 ± 48 [†]	269 ± 60 [†]	428 ± 36 [†]
TAA/Sof-L	19 ± 1 [†]	23 ± 3 [†]	297 ± 36 [†]
TAA/Sof-H	240 ± 63	172 ± 53	329 ± 33
TAA/Dac-L	65 ± 8 [†]	31 ± 4 [†]	219 ± 19 [†]
TAA/Dac-H	36 ± 8 [†]	28 ± 4 [†]	247 ± 35 [†]
TAA/Sof-L/Dac-L	30 ± 10 [†]	29 ± 8 [†]	301 ± 19 [†]

Values are representation of 6-8 observations as means ± S.E.M. Results are considered significantly different when *p* < 0.05. [†]Significant difference compared to control, [‡]significant difference compared to thioacetamide (TAA) hepatic fibrosis group. ALT – alanine aminotransferase, AST – aspartate aminotransferase, ALP – alkaline phosphatase, Sof-L – sofosbuvir in low dose, Sof-H – sofosbuvir in high dose, Dac-L – daclatasvir in low dose, Dac-H – daclatasvir in high dose

Table 2. Effect of sofosbuvir and daclatasvir on oxidative stress parameters in hepatic tissue

	MDA nmol/g tissue	SOD U/g tissue	Catalase U/g tissue
Control	81 ± 10	1748 ± 32	479 ± 36
TAA	140 ± 5 [†]	828 ± 220 [†]	88 ± 11 [†]
TAA/Sof-L	80 ± 1 [†]	1776 ± 25 [†]	387 ± 36 [†]
TAA/Sof-H	135 ± 7	1114 ± 26	244 ± 42
TAA/Dac-L	100 ± 7 [†]	1781 ± 32 [†]	395 ± 44 [†]
TAA/Dac-H	97 ± 3 [†]	1749 ± 26 [†]	403 ± 41 [†]
TAA/Sof-L/Dac-L	105 ± 2 [†]	1690 ± 50 [†]	412 ± 28 [†]

Values are representations of 6-8 observations as means ± S.E.M. Results are considered significantly different when *p* < 0.05. [†]Significant difference compared to control, [‡]significant difference compared to thioacetamide (TAA) hepatic fibrosis group. MDA – malondialdehyde, SOD – superoxide dismutase, Sof-L – sofosbuvir in low dose, Sof-H – sofosbuvir in high dose, Dac-L – daclatasvir in low dose, Dac-H – daclatasvir in high dose

Table 3. Effect of sofosbuvir and daclatasvir on TNF- α and TIMP-1 in hepatic tissue

	TNF- α (ng/g tissue)	TIMP-1 (pg/g tissue)
Control	27 \pm 6	707 \pm 70
TAA	127 \pm 19 [†]	1650 \pm 145 [†]
TAA/Sof-L	25 \pm 8 [‡]	537 \pm 81 [‡]
TAA/Sof-H	106 \pm 20	1231 \pm 195
TAA/Dac-L	40 \pm 3 [‡]	614 \pm 93 [‡]
TAA/Dac-H	41 \pm 4 [‡]	619 \pm 53 [‡]
TAA/Sof-L/Dac-L	37 \pm 7 [‡]	789 \pm 27 [‡]

Values are representations of 6-8 observations as means \pm S.E.M. Results are considered significantly different when $p < 0.05$. [†]Significant difference compared to control, [‡]significant difference compared to thioacetamide (TAA) hepatic fibrosis group. Sof-L – sofosbuvir in low dose, Sof-H – sofosbuvir in high dose, Dac-L – daclatasvir in low dose, Dac-H – daclatasvir in high dose, TNF- α – tumor necrosis factor alpha, TIMP-1 – tissue inhibitor of metalloproteinases-1

non-treated TAA group. The TAA group treated with a high dose of Sof did not show a significant difference as compared with the TAA group regarding either MDA content or SOD and catalase activities (Table 2).

Effect of sofosbuvir and daclatasvir on TNF- α and TIMP-1 in hepatic tissue

There was a significant increase in hepatic tissue content of both the inflammatory mediator TNF- α , and the fibrotic marker TIMP-1, in the TAA group when compared with the normal control group (Table 3). The TAA rats that received Sof and/or Dac in a low dose showed

a significant decrease in hepatic tissue content of TNF- α and TIMP-1 in comparison with the TAA group. TAA rats treated with a high dose of Sof showed no significant difference in hepatic TNF- α and TIMP-1 when compared with the model group (Table 3).

Effect of sofosbuvir and daclatasvir on histopathological staining of hepatic tissue

In histopathological examination (Figure 2 and Table 4), the TAA group showed a significant increase in the necro-inflammatory foci (Figure 1B) as compared with the control group (Figure 1A). However, TAA rats receiving either Sof or Dac in low doses (Figures 1C and 1E, respectively), or their combination (Figure 1G), as well as Dac in a high dose (Figure 1F), showed significant attenuation of the necro-inflammatory changes. In the group treated with a high dose of Sof, there was no significant change in the inflammatory foci (Figure 1D).

Masson trichrome stain showed normal collagen distribution in the control group (Figure 2A). The TAA group showed significantly more collagen fibers than control, with over-bridging between the central vein and another central vein (Figure 2B). Animals that received either Sof or Dac in low doses (Figures 2C and 2E, respectively), or their combination (Figure 2G) as well as Dac in a high dose (Figure 2F) showed almost normal collagen distribution. In rats administered with a high dose of Sof (Figure 1D), there was no significant change in collagen distribution compared with the TAA model group (Table 4).

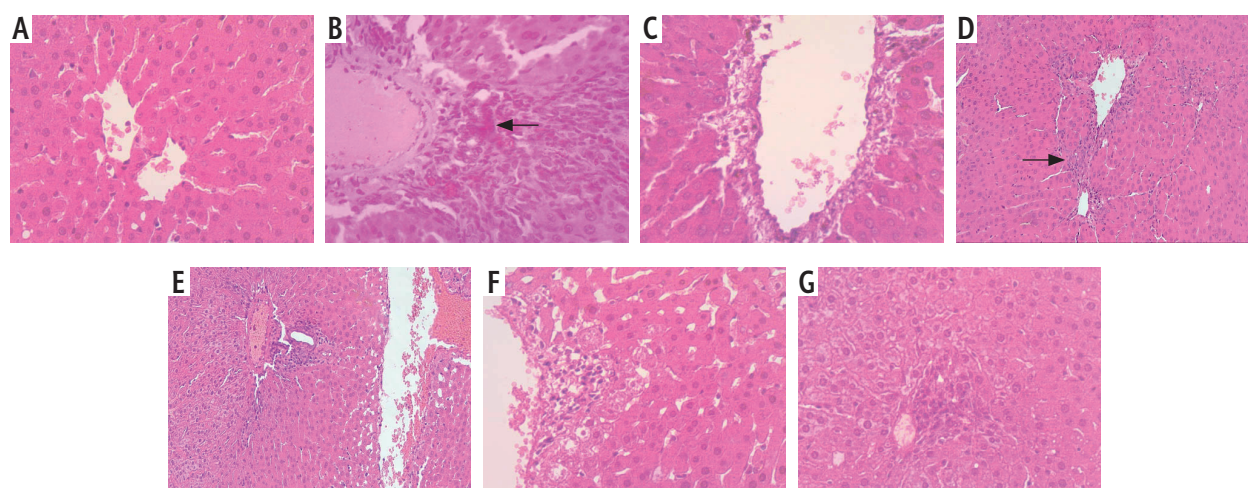


Fig. 1. Effect of sofosbuvir and daclatasvir on histopathological picture hematoxylin and eosin (H&E) staining on thioacetamide (TAA)-induced hepatic fibrosis in rats. Localization of necroinflammation in the liver tissue of **A)** control group, **B)** TAA-treated group and **C, D, E,** and **F)** for concomitant TAA-treated groups with sofosbuvir in low or high doses, or daclatasvir in low or high doses, respectively, and **G)** for TAA-treated with both sofosbuvir and daclatasvir in a low dose. Black arrows show piecemeal and confluent necrosis with focal inflammation. Table 4 shows analysis of necroinflammation score in H&E staining

Discussion

Treatment of HCV with DAAs is one of the most successful tools that prevent progression of the diseased liver into liver fibrosis. However, there are no data regarding the direct effect of DAAs on liver injury in absence of HCV infection.

In the current study, TAA-induced liver injury was indicated by elevation of liver enzymes and confirmed by histopathological examination that showed evidence of liver inflammation and fibrosis. Induction of liver injury TAA was accompanied by an increase in hepatic tissue contents of oxidative stress parameters, the inflammatory mediator TNF- α , and the mediator of fibrosis TIMP-1. The present results were consistent with the previous studies. It has been reported that TAA-induced liver injury was accompanied by increased liver MDA, along with decreased SOD and catalase enzymatic activities [21]. Liver injuries including HCV are inducers of pro-inflammatory cytokines including TNF- α . Modulation of such mediators may affect the prognosis of liver injury [22]. Liver fibrosis complicating chronic HCV is assessed by different serum markers including TIMP-1 [23].

In the present study, treatment of rats with therapeutic doses of either Sof and/or Dac resulted in significant amelioration of TAA-induced liver injury. Such a hepatoprotective effect of the tested drugs was confirmed histopathologically, where it showed a significant reduction of the inflammatory foci in H&E stained liver sections as well as a significant decrease of the fibrotic changes in Masson trichrome stained liver sections. The protective effect of tested drugs was associated with significant amelioration

Table 4. Effect of sofosbuvir and daclatasvir on histopathological score of hepatic tissue

	Necroinflammation score	Fibrosis score
Control	0.25 \pm 0.25	0.33 \pm 0.33
TAA	4.30 \pm 0.25 [†]	5.00 \pm 0.01 [†]
TAA/Sof-L	1.50 \pm 0.29 [‡]	3.33 \pm 0.33 [‡]
TAA/Sof-H	3.50 \pm 0.50	4.70 \pm 0.33
TAA/Dac-L	1.80 \pm 0.50 [‡]	3.33 \pm 0.33 [‡]
TAA/Dac-H	1.00 \pm 0.01 [‡]	3.33 \pm 0.33 [‡]
TAA/Sof-L/Dac-L	1.50 \pm 0.30 [‡]	3.33 \pm 0.33 [‡]

Values are representations of 6-8 observations as means \pm S.E.M. Results are considered significantly different when $p < 0.05$. [†]Significant difference compared to control, [‡]significant difference compared to thioacetamide (TAA) hepatic fibrosis group. Sof-L – sofosbuvir in low dose, Sof-H – sofosbuvir in high dose, Dac-L – daclatasvir in low dose, Dac-H – daclatasvir in high dose

of the oxidative stress parameters as well as by a significant reduction of TNF- α and TIMP-1.

To the best of our knowledge, these findings are the first demonstrating the hepatoprotective effects of Sof and/or Dac in TAA-induced liver injury.

Chemically, Sof is a nucleoside analogue. The hepatic effect of nucleoside analogues is an issue of controversy. It has been reported that nucleotide analogues showed a hepatoprotective effect in alcoholic-induced liver injury via an antioxidant mechanism [10]. Other studies reported anti-tumor and antioxidant effects of nucleosides [11].

The molecular mechanisms underlying the hepatoprotective effects of Sof and Dac need further investigations. It is well known that, in response to liver

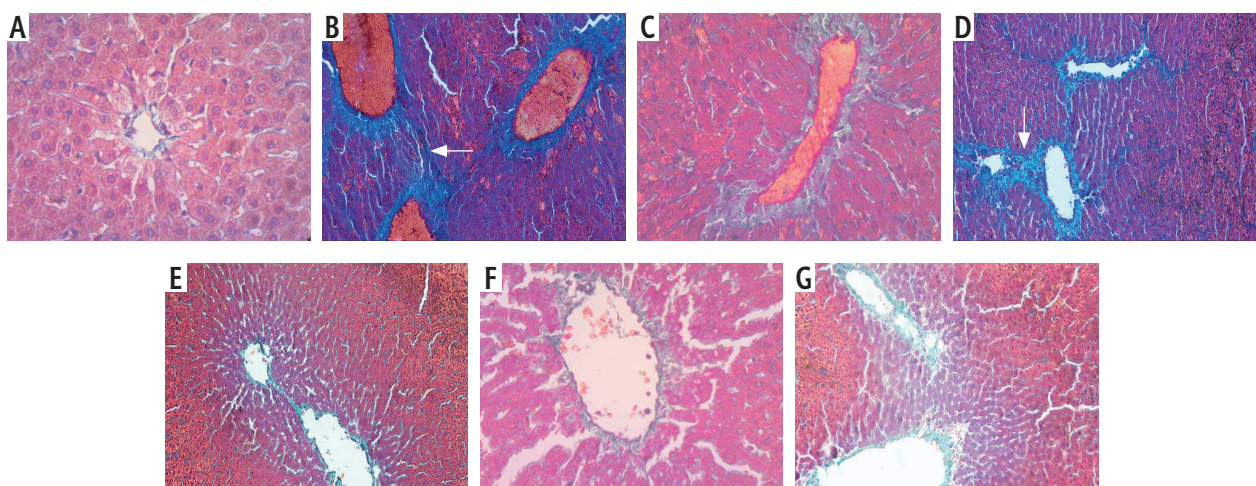


Fig. 2. Effect of sofosbuvir and daclatasvir in histopathological picture using Masson trichrome staining on thioacetamide (TAA)-induced hepatic fibrosis in rats. Localization of deposition of collagen fibers and over-bridging between central vein and portal tract and also between central vein and other central vein ($\times 40$) in the liver tissue of **A**) control, **B**) TAA-treated group and **C, D, E,** and **F**) for concomitant TAA-treated groups with sofosbuvir in low or high doses, or daclatasvir in low or high doses, respectively, and **G**) for TAA-treated groups with both sofosbuvir and daclatasvir in low doses. Black arrows show deposition of collagen fibers and over-bridging between central vein and another central vein. Table 4 shows analysis of fibrosis score in Masson staining

injury, several types of cells including Kupffer cells, natural killer cells, and lymphocytes secrete proinflammatory and profibrogenic mediators including transforming growth factor- β , interleukin-1 β , and TNF- α . These mediators, as well as reactive oxygen species that accompany liver injury, convert stellate cells from the quiescent form into active proliferative fibrogenic cells, which are the main source of collagen, extracellular matrix and metalloproteinase. As the activated stellate cells also secrete TIMP-1, the activities of metalloproteinase were relatively suppressed, resulting in deposition of collagen and development of liver fibrosis [24, 25]. Similarly, TIMP-1 was upregulated during liver injury, including HCV, to promote fibrosis in the injured liver by inhibition of matrix metalloproteinase and degradation of extracellular matrix [26]. Interestingly, in contrast with the therapeutic dose of Sof, the current research showed that the high dose of Sof did not significantly improve TAA-induced liver fibrosis. There is no clear explanation for the differential effect of the therapeutic versus the high dose of Sof in TAA-induced liver injury. Such a finding might be partially explained by previous studies that reported a possible hepatotoxic effect of Sof in patients with advanced liver diseases. The hepatotoxic effect of Sof was attributed to the accumulation of a high concentration of its metabolites [27, 28]. Sof is activated in the liver by hydrolysis and phosphorylation to the triphosphate GS-461203, the active form, then dephosphorylated to the inactive metabolite (GS-331077). The half-lives of Sof and its active metabolite are 0.4 hours and 27 hours, respectively. Following a single 400 mg oral dose of Sof, 80% is excreted in urine, 14% in feces, and 2.5% in expired air recovery [4]. Additionally, it has been reported that high doses (not therapeutic doses) of the purine analogues abacavir and didanosine caused further deterioration of acetaminophen-induced hepatic injury [9]. Similarly, some drugs may act as antioxidants in small doses and pro-oxidants in high doses [29].

Conclusions

The results of the present study indicated that therapeutic doses of the DAAs Sof and Dac are hepatoprotective. Such effects were attributed to their antioxidant effect as well as to the decrease in hepatic tissue content of TNF- α and TIMP-1. In contrast, a high dose (double the therapeutic dose) of Sof produced no improvement in TAA-induced liver injury in rats. The results of the current study indicate that HCV patients who are going to use these drugs should adhere to the therapeutic doses and be aware of the possible hepatotoxic effect of

a large dose of Sof. Further experiments with prolonged duration of studies and different models of liver injury are needed to confirm the results of the current study.

Acknowledgement

The authors thank Professor Osama Ashour for helping in revision of the English grammar of the manuscript.

Disclosure

The authors report no conflict of interest.

References

1. Ringehan M, McKeating JA, Protzer U. Viral hepatitis and liver cancer. *Philos Trans R Soc Lond B Biol Sci* 2017; 372: 1732.
2. Yang YM and Choi EJ. Efficacy and safety outcomes of sofosbuvir-based treatment regimens for hepatitis C virus-infected patients with or without cirrhosis from phase III clinical trials. *Ther Clin Risk Manag* 2017; 13: 477-497.
3. Li G and De Clercq E. Current therapy for chronic hepatitis C: The role of direct-acting antivirals. *Antiviral Res* 2017; 142: 83-122.
4. Geddayy A, Ibrahim YF, Elbahie NM, et al. Direct Acting Anti-hepatitis C Virus Drugs: Clinical Pharmacology and Future Direction. *J Transl Int Med* 2017; 5: 8-17.
5. Guarino M, Morisco F, Valvano MR, et al. Systematic review: interferon-free regimens for patients with HCV-related Child C cirrhosis. *Aliment Pharmacol Ther* 2017; 45: 1193-1200.
6. Bernuth S, Yagmur E, Schuppan D, et al. Early changes in dynamic biomarkers of liver fibrosis in hepatitis C virus-infected patients treated with sofosbuvir. *Dig Liver Dis* 2016; 48: 291-297.
7. Abdel-Aziz A, Ibrahim M, El-Sheikh A, et al. Effect of Sofosbuvir Plus Daclatasvir in Hepatitis C Virus Genotype-4 Patients: Promising Effect on Liver Fibrosis. *J Clin Exp Hepatol* 2018; 8: 15-22.
8. Dyson JK, Hutchinson J, Harrison L, et al. Liver toxicity associated with sofosbuvir, an NS5A inhibitor and ribavirin use. *J Hepatol* 2016; 64: 234-238.
9. Blas-Garcia A, Marti-Rodrigo A, Victor VM, et al. The purine analogues abacavir and didanosine increase acetaminophen induced hepatotoxicity by enhancing mitochondrial dysfunction. *J Antimicrob Chemother* 2016: 916-926.
10. Cai X, Bao L, Wang N, et al. Dietary Nucleotides Supplementation and Liver Injury in Alcohol-Treated Rats: A Metabolomics Investigation. *Molecules* 2016; 21: 435.
11. Da Rosa RM, Dornelles L, Rodrigues OED, et al. Synthesis, antioxidant and antitumor activities of 5'-arylchalcogeno-3-aminothymidine (ACAT) derivatives. *Med Chem Commun* 2017; 8: 408-414.
12. Nawaz R, Zahid S, Idrees M, et al. HCV-induced regulatory alterations of IL-1 β , IL-6, TNF- α , and IFN- γ in non-alcoholic steatohepatitis. *Inflamm Res* 2017; 66: 477-486.
13. Medvedev R, Ploen D and Hildt E. HCV and Oxidative Stress: Implications for HCV Life Cycle and HCV-Associated Pathogenesis. *Oxid Med Cell Longev* 2016; 2016: 9012580.
14. Apte UM, Limaye PB, Desai D, et al. Mechanisms of increased liver tissue repair and survival in diet-restricted rats treated with equitoxic doses of thioacetamide. *Toxicol Sci* 2003; 72: 272-282.

15. Hamed G, Bahgat N, Abdel Mottaleb F, et al. Effect of flavonoid quercetin supplement on the progress of liver cirrhosis in rats. *Life Sci J* 2011; 8: 641-651.
16. Shin JW, In-Chan Seol IN, and Son CG. Interpretation of Animal Dose and Human Equivalent Dose for Drug Development. *J Korean Oriental Med* 2010; 31: 1-7.
17. Buege JA and Aust SD. Microsomal lipid peroxidation. *Methods Enzymol* 1978; 52: 302-310.
18. Marklund S and Marklund G. Involvement of the superoxide anion radical in the autoxidation of pyrogallol and a convenient assay for superoxide dismutase. *Eur J Biochem* 1974; 47: 469-474.
19. Aebi H. Catalase in vitro. *Methods Enzymol* 1984; 105: 121-126.
20. Ishak K, Baptista A, Bianchi L, et al. Histological grading and staging of chronic hepatitis. *J Hepatol* 1995; 22: 696- 699.
21. Ying L, Yan F, Zhao Y, et al. (-)-Epigallocatechin-3-gallate and atorvastatin treatment down-regulates liver fibrosis-related genes in non-alcoholic fatty liver disease. *Clin Exp Pharmacol Physiol* 2017; 44: 1180-1191.
22. Del Campo JA, Gallego P, Grande L. Role of inflammatory response in liver diseases: Therapeutic strategies. *World J Hepatol* 2018; 10: 1-7.
23. Omran D, Yosry A, Darweesh SK, et al. Enhanced liver fibrosis test using ELISA assay accurately discriminates advanced stage of liver fibrosis as determined by transient elastography fibroscan in treatment naïve chronic HCV patients. *Clin Exp Med* 2018; 18: 45-50.
24. Miao CG, Yang YY, He X, et al. signaling in liver fibrosis: progress, challenges and potential directions. *Biochimie* 2013; 95: 2326-2335.
25. Heeba GH and Mahmoud ME. Therapeutic potential of morin against liver fibrosis in rats: modulation of oxidative stress, cytokine production and nuclear factor kappa B. *Environ Toxicol Pharmacol* 2014; 37: 662-671.
26. Osawa Y, Hoshi M, Yasuda I, et al. Tumor necrosis factor-alpha promotes cholestasis-induced liver fibrosis in the mouse through tissue inhibitor of metalloproteinase-1 production in hepatic stellate cells. *PLoS One* 2013; 8: e65251.
27. Dyson JK, Hutchinson J, Harrison L, et al. Liver toxicity associated with sofosbuvir, an NS5A inhibitor and ribavirin use. *J Hepatol* 2016; 64: 234-238.
28. Soriano V, Barreiro P, de Mendoza C, et al. Hepatic decompensation with sofosbuvir plus simeprevir in a patient with Child-Pugh B compensated cirrhosis. *Antivir Ther* 2016; 21: 91-92.
29. El-Sheikh AA, Morsy MA, Mahmoud MM, et al. Effect of coenzyme-q10 on Doxorubicin-induced nephrotoxicity in rats. *Adv Pharmacol Sci* 2012; 2012: 981461.